

REVIEW

Fetal pleural effusion

Maria Angela Rustico, Mariano Lanna, Dario Coviello, John Smoleniec and Umberto Nicolini*

1st Department of Obstetrics and Gynecology, University of Milano, Ospedale Buzzi, Via Castelvetro 32, Milano - Italy

Fetal pleural effusion, a nonspecific accumulation of fluid in the pleural space, is an uncommon anomaly which can be associated with aneuploidy and a range of other structural malformations or genetic syndromes. Spontaneous resolution is not rare and confers a good prognosis. Perinatal outcome is better for those fetuses without hydrops than those presenting with hydrops. A detailed review of the literature indicates that, for fetuses with persistent effusions, *in utero* intervention (repeated thoracocentesis, intrauterine shunting and pleurodesis) may improve the chances of survival. Copyright © 2007 John Wiley & Sons, Ltd.

KEY WORDS: fetus; pleural effusion; hydrops; intrauterine shunting

INTRODUCTION

Fetal pleural effusion refers to a nonspecific accumulation of fluid in the pleural space. In newborn infants, pleural effusion is defined as *chylothorax* when the fluid contains more than 1.1 mmol/L tryglicerides (with oral fat intake), and has a lymphocyte proportion exceeding 80% (Buttiker *et al.*, 1999). Since the fetus is not fed *in utero* and the mean percentage of lymphocytes in the blood of normal fetuses is normally >80% (Poblete *et al.*, 2001), these parameters cannot be used prenatally, hence it is more pertinent to define any accumulation of fluid in the fetal thorax as hydrothorax.

Fetal pleural effusion is a rare condition, whose incidence (reported more than 15 years ago) of 1/10 000–1/15 000 pregnancies is still generally accepted (Longaker *et al.*, 1989).

At prenatal ultrasonography, it appears as a unilateral or bilateral anechoic space in the thorax, surrounding the lungs. The clinical course varies from spontaneous resolution to a progressive increase and the development of hydrops and polyhydramnios, with a high risk of preterm delivery and *in utero* death (Aubard *et al.*, 1998). If severe and long-standing, it has the effect of a space occupying lesion, impeding normal lung development, with the risk of pulmonary hypoplasia and neonatal death (Castillo *et al.*, 1987).

The optimal approach to prenatal management is still a matter of debate (Knox *et al.*, 2006), given that the natural course of the disease can vary, but there is general consensus that pleural effusion is a serious condition with a high rate of perinatal morbidity and mortality, making it advisable in selected cases to offer prenatal therapy (Weber and Philipson, 1992).

ETIOLOGY OF FETAL PLEURAL EFFUSION

In normal conditions, the minute spaces (stomata) between the mesothelial cells of the parietal pleura allow free movement of fluid from and to the pleural space. These stomata communicate directly with lymphatic lacunae, which empty into lymphatic channels and in turn drain into the mediastinal lymph nodes. If there is a disruption to this drainage pathway, lymphatic fluid collects in the pleural space (Sahn, 1990).

Experimental (Hodges *et al.*, 1993) and iatrogenic laceration of the thoracic duct complicating infant intrathoracic surgery for correction of congenital malformations such as oesophageal atresia, results in pleural effusion (Riquet *et al.*, 2002). Moreover, certain cardiovascular interventions complicated by obstruction or high pressure in the venous system have a 23% incidence of postoperative chylothorax (Sade and Wiles, 1990). In fact, when the pressure in the venous system exceeds the pressure in the thoracic duct, rupture of the duct itself or of its collaterals may occur, resulting in chylothorax, as observed in old experimental studies, which involved occlusion of the superior vena cava (Blalock *et al.*, 1936).

In the newborn, although rare, pleural effusion is mainly due to a congenital malformation of the thoracic duct or of the lymphatic system of the lungs, such as pulmonary lymphangectasis (Al-Tawil *et al.*, 2000; Doerr *et al.*, 2001). It is reasonable to suppose that the same etiology might explain many prenatal cases as well. Recent experimental studies suggest that some cases of congenital chylothorax might also be genetic in origin. In fact, defective development of the lymphatic system and thoracic duct leading to chylothorax with respiratory failure and death was found in mice lacking the integrin $\alpha 9\beta 1$, suggesting a role for these adhesion receptors in lymphatic development (Huang *et al.*, 2000). Autosomic recessive inheritance has been observed in a few cases of congenital pulmonary lymphangectasis (Scott–Emuakpor *et al.*, 1981; Moerman *et al.*, 1993).

*Correspondence to: Umberto Nicolini, 1st Department of Obstetrics and Gynecology, University of Milano, Ospedale Buzzi, Via Castelvetro 32, 20155 Milano - Italy.
E-mail: umberto.nicolini@unimi.it

Prenatally, the condition may be an isolated finding (primary pleural effusion) or may occur in association with other conditions (secondary pleural effusion), and may be part of the clinical findings in cases of nonimmune hydrops (Vaughan *et al.*, 1995). Some fetuses with pleural effusion also had diaphragmatic hernia (Smoleniec and James, 1995; Khalil *et al.*, 2005) and other lesions compressing the lungs and mediastinum (congenital cystic adenomatoid malformation and bronchopulmonary sequestration (Adzick *et al.*, 1998)), mediastinal tumours (thyroid teratoma, congenital goitre (Ibrahim *et al.*, 1999)), and cardiac malformations (Skoll *et al.*, 1991). There is a well-known association with chromosomal abnormalities, mainly trisomy 21 (Waller *et al.*, 2005). Other associated conditions include cystic hygroma, congenital infections such as adenovirus, parvovirus B19, herpes simplex virus type 1 (Meyer *et al.*, 1985; Parilla *et al.*, 1997; Dubois-Lebbe *et al.*, 2007), and a number of genetic syndromes (Noonan's and Opitz-Frias hypertelorism hypospadias syndrome (Patton *et al.*, 1986; Bloomfield *et al.*, 1997)). Therefore, prenatal diagnosis of isolated pleural effusion needs to rule out associated fetal conditions by comprehensive detailed ultrasound evaluation of the fetal anatomy, echocardiography and fetal karyotyping, maternal blood count and grouping with antibody status, virology screen including TORCH and parvovirus B19, and Kleihauer-Betke test of the maternal blood (Lam *et al.*, 2003). In many cases, however, the cause of the effusion remains unclear, even after detailed postnatal evaluation.

CLINICAL CONSEQUENCES OF FETAL PLEURAL EFFUSION

Irrespective of the etiology, morbidity and mortality may result from the fetal pleural effusion acting as a space-occupying lesion, especially when associated with pulmonary hypoplasia and fetal hydrops. The mechanism by which hydrops develops is thought to be the increased intrathoracic pressure, which reduces cardiac ventricular dimensions and stroke volume, without impairment in contractility (tamponade effect), resulting in reduced cardiac output (Gonen *et al.*, 1993). The polyhydramnios frequently observed with pleural effusion is probably related to obstruction of the physiological fetal swallowing due to oesophageal compression, and is associated with a high risk of preterm delivery (Murayama *et al.*, 1987). Histological studies have shown that when pleural effusion is persistent, normal pulmonary development is compromised due to a decrease in the number of lung cells, airways and alveoli, resulting in reduced organ size and weight (Castillo *et al.*, 1987). A concomitant decrease in the number of vessels per unit of lung tissue, with increased medial wall thickness, constitutes the morphological basis for raised pulmonary vascular resistance. A few studies have found that the development of pulmonary hypoplasia depends on the time of onset and duration of pleural effusion (Maeda *et al.*, 1989). The associated respiratory dysfunction together

with prematurity, are the main causes of death postnatally (Nakamura *et al.*, 1992).

THE NATURAL HISTORY OF FETAL PLEURAL EFFUSION

There have been few studies which elucidate the natural history of the disorder, but it is generally accepted that the course of pleural effusion is difficult to predict.

Aubard *et al.* (1998) reviewed 204 cases of primary pleural effusion (89 of which did not receive treatment *in utero*) previously reported in 64 articles. In this review, the disorder was detected at a mean gestational age of 27 weeks, and spontaneous regression was observed in 22% of fetuses. The cases most likely to resolve spontaneously presented more often in the second trimester (67%), and were more frequently unilateral (65%), but regression of pleural effusion has been described even in a few hydropic fetuses (Klam *et al.*, 2005). In contrast, some cases of mild pleural effusion may progress rapidly into a severe form with the development of hydrops. Spontaneous regression of unilateral pleural effusion in the second trimester and subsequent recurrence in the bilateral form later on in pregnancy has also been reported (Tarim *et al.*, 2004). Perinatal mortality rate in untreated hydropic fetuses was 52 and 75% in the studies of Longaker *et al.* (1989) and Vaughan *et al.* (1995), respectively. Approximately a quarter of deaths which occur *in utero* are from circulatory abnormalities causing tissue hypoxia and acidemia (Aubard *et al.*, 1998; Mandelbrot *et al.*, 1992), while most postnatal deaths are due to pulmonary hypoplasia (Longaker *et al.*, 1989).

Table 1 summarizes the outcome of 54 reported fetuses (20 publications) with apparently primary pleural effusion which did not undergo intrauterine treatment, and in which gestational age at presentation was reported, the presence or absence of hydrops was described, and perinatal outcome was known. The overall survival rate was 59%, but only 35% in hydropic fetuses.

Table 1—Outcome (numbers and percentages) and gestational age at the first observation (means and ranges) of 54 fetuses reported in the literature with apparently primary pleural effusion which did not undergo *in utero* treatment

	With hydrops N. 20	Without hydrops N. 34	Total N. 54
Gestational age at the first observation (weeks)	—	—	27 (14–37)
TOP	2 (10%)	—	2 (4%)
IUD	3 (15%)	3 (9%)	6 (11%)
NND	8 (40%)	6 (18%)	14 (26%)
Alive	7 (35%)	25 (73%)	32 (59%)

TOP: termination of pregnancy; IUD: intrauterine death; NND: neonatal death.

PRENATAL INTERVENTION FOR FETAL PLEURAL EFFUSION

For a long-time, the rarity of this condition and its unpredictable clinical course prevented a uniform approach to management, and indeed, gave rise to a great deal of uncertainty about the usefulness of any intervention. The meta-analysis by Weber and Philipson (1992) was the first to lend support to the idea of prenatal intervention for fetuses with pleural effusion. The treatment options include thoracocentesis, pleuro-amniotic shunting and pleurodesis.

Thoracocentesis

The procedure is performed under ultrasound control generally using a 20-gauge spinal needle to aspirate the pleural fluid. After multiple aspirations, a small number of pleural effusions can resolve *in utero* (Benacerraf and Frigoletto, 1985; Chen *et al.*, 2001). However, in the majority of cases, reaccumulation of fluid ensues within 1 h–10 days after aspiration (King *et al.*, 1991). One fetal death, secondary to umbilical cord torsion related to the procedure has also been described (Longaker *et al.*, 1989). The procedure has been used occasionally to allow lung expansion prior to delivery, thereby facilitating neonatal resuscitation (Mandelbrot *et al.*, 1992; Gonen *et al.*, 1999). In the already quoted meta-analysis by Aubard *et al.* (1998) the clinical outcome after one or more thoracocenteses performed between 17 and 37 weeks, was very variable. In 13 of 29 (45%) treated cases, the pleural effusion worsened with death of the fetus or infant; in 7 (24%) cases the pleural effusion regressed with a favourable outcome; in 9 (31%) cases there was a good outcome despite the recurrence of the condition. In the presence of hydrops, the survival rate after thoracocentesis was 10%, compared with 60% in non-hydropic fetuses.

Thoraco-amniotic shunting

Because fluid reaccumulates rapidly after aspiration, long-term drainage has been proposed as a more appropriate procedure for treating pleural effusion and was first described by Seeds and Bowes (1986). The most widely used fetal catheter is the Rocket double pigtail silastic catheter (Rocket of London Ltd, Watford, UK) with lateral holes around the coils. The technique employs a metal cannula with trocar inserted transabdominally into the fetal chest, under ultrasound control. An introducer rod is then used to position one end of a double-pigtail catheter. The trocar is then withdrawn into the amniotic cavity to position the other end of the catheter outside the chest wall. Both coils are at right angles to the rest of the catheter and dislodgement is therefore unlikely (Rodeck *et al.*, 1988). The Harrison shunt (Cook Urological, Spencer, Ind., USA) is a polyethylene catheter with side holes at both ends, and is available in different lengths and diameters. It is smaller and more flexible than the Rocket shunt,

but dislodgement and migration may occur (Sepulveda *et al.*, 2005). Similar problems have been reported with a 4F-angiographic single pigtail catheter (Cordis, Johnson&Johnson, The Netherlands) used in some series (Sepulveda *et al.*, 2005). The Denver shunt, made of silicone rubber, was initially developed for the treatment of ventriculomegaly. At present, its production has been discontinued due to the frequency of shunt occlusion at the level of the one-way valve which should have prevented reverse flow (Pandya and Rodeck, 2001).

Although a few studies have reported that around 20% of shunts migrate or obstruct (Wittman *et al.*, 1997; Sepulveda *et al.*, 2005), in most cases the shunt is effective in achieving permanent decompression of pleural effusion. This is demonstrated by reversal of hydrops after the procedure (13/28 cases reported by Nicolaidis and Azar, 1990), and by the incidence of respiratory morbidity (37%) in infants undergoing thoraco-amniotic shunting for fetal pleural effusion and hydrops, which is similar to that found in an unselected group of infants born at term (Thompson *et al.*, 1993). Besides isolated reports of fetal bleeding, scarring and formation of constricting bands (Brown and Nicolaidis, 2000; Webb *et al.*, 2000), the most common complications arising with shunting seem to be premature rupture of the membranes, preterm labor and chorioamnionitis (Picone *et al.*, 2004).

Pleurodesis

Based on the experience in adult patients, fetal intrapleural injection of OK-432 (a lyophilized form of an avirulent strain of streptococcal cells with glycolytic and enzymatic properties), which causes the pleura to become infiltrated by inflammatory cells and adhere to the surface of the lung, was reported for the first time by Tanemura *et al.* (2001) and Okawa *et al.* (2001). Data on this new procedure are very limited and there have been only 9 cases reported so far, five of which were successful (Jorgensen *et al.*, 2003; Tsukihara *et al.*, 2004; Chen *et al.*, 2005a, b). One case of maternal death due to amniotic fluid embolism occurred 8 weeks after OK-432 pleurodesis. Although probably unrelated to the procedure, this death is obviously of considerable concern (Chen *et al.*, 2005b).

Another way of bringing about pleurodesis is by intrapleural injection of maternal blood, with the aim of creating a thrombotic patch. Parra *et al.* (2003) treated successfully with this approach one case of fetal pleural effusion with ascites.

A MEDLINE search of all relevant English language publications between 1977 and 2006, plus manual cross-checking of the reference lists of the pertinent articles, allowed the collection of 59 articles (for a total of 203 cases) dealing with antenatal treatment of apparently primary pleural effusion in which gestational age at diagnosis was reported, the presence or absence of hydrops was described, and perinatal outcome was known. The additional 20 publications reporting 54 untreated fetuses, mentioned in the previous section, have been added to analyze the distribution of gestational age at diagnosis.

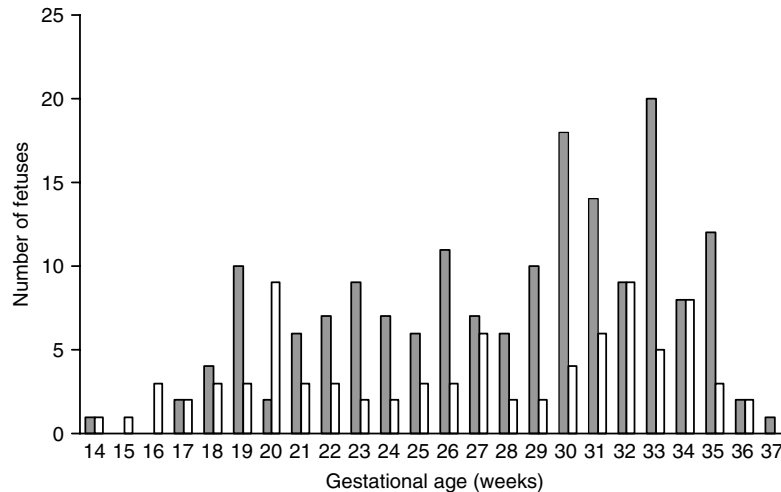


Figure 1—Gestational age at the time of diagnosis and/or antenatal treatment of 257 fetuses with apparently primary pleural effusion reported in the literature with (gray bars) or without (white bars) hydrops

Figure 1 shows that this is a disease, which may occur throughout the whole gestation, but most commonly in the early third trimester: the mode is in fact 32 and 33 weeks' gestation for nonhydropic and hydropic fetuses, respectively (Figure 1).

Table 2 displays the outcome of the 203 fetuses undergoing different treatment options. The presence of hydrops was associated with a worse outcome irrespective of treatment, and survival ranged from 50 to 62%

Table 2—Outcome (numbers and percentages) and gestational age at the first observation (means and ranges) of 203 fetuses reported in the literature with apparently primary pleural effusion which underwent different treatment options

	With hydrops	Without hydrops	Total
Thoracocentesis	N. 22	N. 13	N. 35
Gestational age at treatment (weeks)	—	—	29 (17–36)
TOP	3 (14%)	—	3 (9%)
IUD	1 (4%)	—	1 (3%)
NND	7 (32%)	3 (23%)	10 (28%)
Alive	11 (50%)	10 (77%)	21 (60%)
Thoraco-amniotic shunting	N. 125	N. 33	N. 158
Gestational age at treatment (weeks)	—	—	26 (16–35)
TOP	4 (3%)	3 (9%)	7 (4%)
IUD	20 (16%)	—	20 (13%)
NND	24 (19%)	3 (9%)	27 (17%)
Alive	77 (62%)	27 (82%)	104 (66%)
Pleurodesis	N. 6	N. 4	N. 10
Gestational age at treatment (weeks)	—	—	25 (14–31)
TOP	—	—	—
IUD	2	—	2 (20%)
NND	1	1	2 (20%)
Alive	3	3	6 (60%)

TOP: termination of pregnancy; IUD: intrauterine death; NND: neonatal death.

in these fetuses. Although not significant, the best outcome, both for hydropic and nonhydropic fetuses, was achieved through thoraco-amniotic shunting.

Personal experience

Between 1992 and July 2005, 53 pregnant women, who were referred to our tertiary fetal medicine unit, underwent thoraco-amniotic shunting for fetal pleural effusion. All patients had extensive investigation prior to the procedure, including a detailed fetal anatomy scan and karyotyping. Occasionally, chromosome analysis was performed at the time of shunting. Maternal blood was investigated for antibodies and viral infection. Shunting was indicated because the pleural effusion was complicated by hydrops (defined as coexisting ascites and/or skin edema) and/or polyhydramnios. All shunts (double pigtail catheter (Rocket, London, UK)) were inserted by one operator (UN) under ultrasound guidance using local anesthesia. In all 88 shunt placements (35 bilateral and 18 unilateral effusions) the procedure was successful. In only two instances the shunt was found free floating in the amniotic cavity a few days after shunting, and the procedure had to be repeated. In addition, pleural effusion recurred in two fetuses despite the shunt being *in situ*. This was thought to be caused by blockage of the catheter and a second shunt was inserted successfully.

The clinical and sonographic characteristic of the 53 cases are summarized in Table 3.

Two hydropic fetuses were terminated because of an abnormal karyotype (1 trisomy 21, 1 trisomy 12). There were 12 neonatal deaths. Autopsy reported pulmonary hypoplasia in 5 of the 10 cases in which the information was available (2 with left diaphragmatic hernia, 1 with pulmonary lymphangectasis). Three additional malformations (1 hypoplastic left ventricle, 1 Costello syndrome, 1 mucopolysaccharidosis) were diagnosed at postmortem examination. In two cases, neonatal death occurred on account of intractable cardiocirculatory failure.

Table 3—Personal experience. Clinical and sonographic characteristics of 53 fetuses with pleural effusion treated by thoraco-amniotic shunting

	With hydrops N. 43	Without hydrops N. 10	Total N. 53
GA at shunting (weeks)			
</ = 24	7 (16%)	4 (40%)	11 (21%)
25–28	12 (28%)	1 (10%)	13 (25%)
29–32	21 (49%)	4 (40%)	25 (47%)
>32	3 (7%)	1 (10%)	4 (7%)
Duration of shunting (weeks)			
<2	14 (33%)	1 (10%)	15 (29%)
2–4	10 (24%)	3 (30%)	13 (25%)
>4	18 (43%)	6 (60%)	24 (46%)
Associated anomalies (*)			
Severe (%)	10 (23)	1 (10)	11 (21)
Not severe (%)	2 (5)	3 (30)	5 (9)
Outcome			
TOP	2 (5)	—	2 (4%)
IUD	5 (12%)	—	5 (9%)
NND	11 (25%)	1 (10%)	12 (23%)
Alive (**)	25 (58%)	9 (90%)	34 (64%)

Numbers and percentages (%). (*) Severe associated anomalies in fetuses with hydrops: 3 diaphragmatic hernia; 1 Noonan syndrome; 1 Costello syndrome; 1 mucopolysaccharidosis; 1 hypoplastic left ventricle; 1 post-ductal aortic coarctation; 1 trisomy 21; 1 trisomy 12. Not severe associated anomalies in fetuses with hydrops: 1 mild mitral valve stenosis; 1 sensorineural hearing loss. Severe associated anomalies in fetuses without hydrops: 1 hypoplastic aortic arch. Not severe associated anomalies in fetuses without hydrops: 1 Leber's amaurosis; 1 ventricular septal defect/esadactily/ectopic kidney; 1 vesico-ureteral reflux. (***) Two infants have serious sequelae: 1 psychomotor delay due to kernikterus; 1 intraventricular haemorrhage grade 1 and thrombosis of superior vena cava.

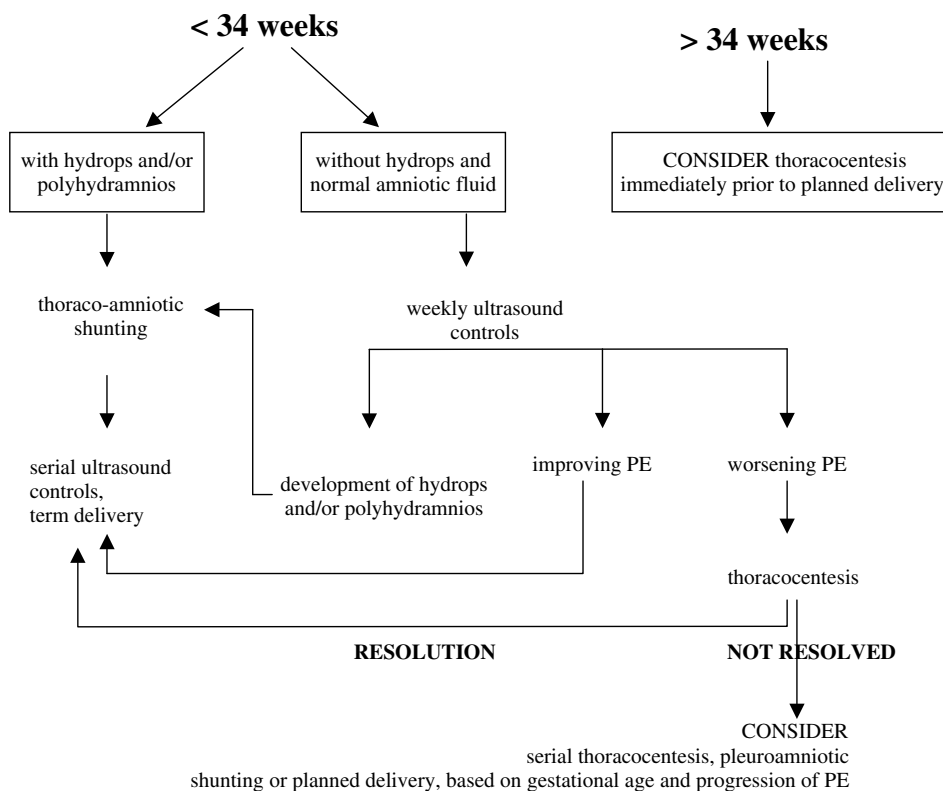


Figure 2—Proposed algorithm for the management of apparently primary fetal pleural effusion

There were 34 survivors: 58% of those fetuses which were hydropic at shunting and 90% of those which were not. At follow up, ranging 1–7 years, 10 infants had clinical abnormalities and there were 24 intact survivors (45%).

Although the heterogeneous nature of the studies reported in the literature (case reports, small case series) precludes a strong evidence on the comparative efficacy of each technique, a clinical algorithm to outline the management of this condition may assist the clinical practice (Figure 2).

CONCLUSIONS

Fetal pleural effusion is an uncommon anomaly which can be associated with aneuploidy and a range of other structural malformations or genetic syndromes, which in many cases may be evident only after postnatal examination. The large number of associations necessitates comprehensive fetal and maternal investigations before offering prognostic counseling regarding prenatal treatment. Spontaneous resolution can occur in which case the prognosis is good. Survival for fetuses with persistent effusions following *in utero* intervention appears better for those without hydrops (around 80%) than those presenting with hydrops (around 60%).

Whilst no randomized study of pleuro-amniotic shunting has been performed, the accumulated literature would suggest that this procedure may improve outcome, particularly for fetuses that have or develop hydrops.

REFERENCES

- Adzick NS, Harrison MR, Crombleholme TM, Flake AW, Howell LJ. 1998. Fetal lung lesions: management and outcome. *Am J Obstet Gynecol* **179**: 884–889.
- Al-Tawil K, Ahmed G, Al-Hathal M, Al-Jarallah Y, Campbell NC. 2000. Congenital chylothorax. *Am J Perinatol* **17**: 121–126.
- Aubard J, Derouineau I, Aubard V, Chalifour V, Preux PM. 1998. Primary fetal hydrothorax: a literature review and proposed antenatal clinical strategy. *Fetal Diagn Ther* **13**: 325–333.
- Benacerraf BR, Frigoletto FD. 1985. Mid-trimester fetal thoracocentesis. *J Clin Ultrasound* **13**: 202–204.
- Blalock A, Cunningham RS, Robinson CS. 1936. Experimental production of chylothorax by occlusion of the superior vena cava. *Ann Surg* **104**: 359–364.
- Bloomfield FH, Hadden W, Gunn TR. 1997. Lymphatic dysplasia in a neonate with Noonan's syndrome. *Pediatr Radiol* **27**: 321–323.
- Brown R, Nicolaidis K. 2000. Constriction band of the arm following insertion of a pleuro-amniotic shunt. *Ultrasound Obstet Gynecol* **15**: 439–440.
- Buttiker V, Fanconi S, Burger R. 1999. Chylothorax in children. Guidelines for diagnosis and management. *Chest* **116**: 682–687.
- Castillo RA, Devoe LD, Falls G, Holzman GB, Hadi HA, Fadel HE. 1987. Pleural effusions and pulmonary hypoplasia. *Am J Obstet Gynecol* **157**: 1252–1255.
- Chen CP, Chang TY, Wang W. 2001. Resolution of fetal bilateral chylothorax and ascites after two unilateral thoracocenteses. *Ultrasound Obstet Gynecol* **18**: 401–402.
- Chen M, Chen CP, Shih JC, et al. 2005a. Antenatal treatment of chylothorax and cystic hygroma with OK-432 in nonimmune hydrops fetalis. *Fetal Diagn Ther* **20**: 309–315.
- Chen M, Shih JC, Wang BT, Chen CP, Yu CL. 2005b. Fetal OK-432 pleurodesis: complete or incomplete? *Ultrasound Obstet Gynecol* **26**: 791–793.
- Doerr CH, Miller DL, Ryu JH. 2001. Chylothorax. *Semin Respir Crit Care Med* **22**: 617–626.
- Dubois-Lebbe C, Houfflin-Debarge V, Dewilde A, Devisme L, Subtil D. 2007. Nonimmune hydrops fetalis due to herpes simplex virus type 1. *Prenat Diagn* **27**: 184–189.
- Gonen R, Degani S, Shapiro I, Samberg I, Sharf M. 1993. The effect of drainage of fetal chylothorax on cardiac and blood vessel hemodynamics. *J Clin Ultrasound* **21**: 265–268.
- Gonen R, Degani S, Kugelman A, Abend M, Bader D. 1999. Intrapartum drainage of fetal pleural effusion. *Prenat Diagn* **19**: 1124–1126.
- Hodges CC, Fossum TW, Evering W. 1993. Evaluation of thoracic duct healing after experimental laceration and transection. *Vet Surg* **22**: 431–435.
- Huang XZ, Wu JF, Ferrando R, et al. 2000. Fatal chylothorax in mice lacking the integrin $\alpha 9 \beta 1$. *Mol Cell Biol* **20**: 5208–5215.
- Ibrahim H, Asamoah A, Krouskop RW, Lewis D, Webster P, Pramnik AK. 1999. Congenital chylothorax in neonatal thyrotoxicosis. *J Perinatol* **19**: 68–71.
- Jorghensen C, Brocks V, Bang J, Jorgensen S, Ronsbro L. 2003. Treatment of severe fetal chylothorax associated with pronounced hydrops with intrapleural injection of OK-432. *Ultrasound Obstet Gynecol* **21**: 66–69.
- Khalil BA, Jesudason EC, Featherstone NC, et al. 2005. Hidden pathologies associated with (and concealed by) early gestational isolated fetal hydrothorax. *J Pediatr Surg* **40**: e1–e3.
- King PA, Ghosh A, Tang MHY, Lam SK. 1991. Recurrent congenital chylothorax. *Prenat Diagn* **11**: 809–811.
- Klam S, Bigras JL, Hudon L. 2005. Predicting outcome in primary fetal hydrothorax. *Fetal Diagn Ther* **20**: 366–370.
- Knox EM, Kilby MD, Martin WL, Khan KS. 2006. In-utero pulmonary drainage in the management of primary hydrothorax and congenital cystic lung lesion: a systematic review. *Ultrasound Obstet Gynecol* **28**: 726–734.
- Lam H, Yates R, Jauniaux E. 2003. Successful early in utero management of fetal hydrothorax in a twin pregnancy. *Prenat Diagn* **23**: 221–224.
- Longaker MT, Laberge JM, Dansereau J, et al. 1989. Primary fetal hydrothorax: natural history and management. *J Pediatr Surg* **24**: 573–576.
- Maeda H, Shimokawa H, Yamaguchi Y, Sueishi K, Nakano H. 1989. The influence of pleural effusion on pulmonary growth in the human fetus. *J Perinat Med* **17**: 231–234.
- Mandelbrot L, Dommergues M, Aubry MC, Mussat P, Dumez Y. 1992. Reversal of fetal distress by emergency in utero decompression of hydrothorax. *Am J Obstet Gynecol* **167**: 1278–1283.
- Meyer K, Girsig N, McGravey V. 1985. Adenovirus associated with congenital pleural effusion. *J Pediatr* **107**: 433–435.
- Moerman P, Vandenberghe K, Devlieger H, Van Hole C, Fryns JP, Lauweryns JM. 1993. Congenital pulmonary lymphangiectasis with chylothorax: a heterogeneous lymphatic vessel abnormality. *Am J Med Genet* **47**: 54–58.
- Murayama K, Jimbo T, Matsumoto Y, Mitsuishi C, Nishida H. 1987. Fetal pulmonary hypoplasia with hydrothorax. *Am J Obstet Gynecol* **157**: 119–120.
- Nakamura Y, Harada K, Yamamoto I, et al. 1992. Human pulmonary hypoplasia. Statistical, morphological, morphometric and biochemical study. *Arch Pathol Lab Med* **116**: 635–642.
- Nicolaidis KH, Azar GB. 1990. Thoraco-amniotic shunting. *Fetal Diagn Ther* **5**: 153–164.
- Okawa T, Takano Y, Fujimori KL, Yanagida K, Sato A. 2001. A new fetal therapy for chylothorax: pleurodesis with OK-432. *Ultrasound Obstet Gynecol* **18**: 376–377.
- Pandya PP, Rodeck CH. 2001. Percutaneous sonographically guided interventions: catheters and shunts. In *The Unborn Patient*, Harrison MR, Evans MI, Adzick NS, Holzgreve W (eds). WB Saunders: Philadelphia, PA; 191–197.
- Parilla BV, Tamura RK, Ginsberg NA. 1997. Association of parvovirus infection with isolated fetal effusions. *Am J Perinatol* **14**: 357–358.
- Parra J, Amenado M, Muniz-Diaz E, et al. 2003. A new successful therapy for fetal chylothorax by intrapleural injection of maternal blood. *Ultrasound Obstet Gynecol* **22**: 290–294.
- Patton MA, Baraitser M, Nicolaidis KH, Rodeck CH, Gamsu H. 1986. Prenatal treatment of fetal hydrops associated with the

- hypertelorism-dysphagia syndrome (Opitz-G syndrome). *Prenat Diagn* **6**: 109–115.
- Picone O, Benachi A, Mandelbrot L, Ruano R, Dumez Y, Dommergues M. 2004. Thoracoamniotic shunting for fetal pleural effusions with hydrops. *Am J Obstet Gynecol* **191**: 2047–2050.
- Poblete A, Roberts A, Trespidi L, Guarneri D, Bonati F, Nicolini U. 2001. Fetal and maternal white cells and B- and T- lymphocyte subpopulations in pregnant women with recent infection. *Fetal Diagn Ther* **16**: 378–383.
- Riquet M, Le Pimpec Barthes F, Souilamas R, Hidden G. 2002. Thoracic duct tributaries from intrathoracic organs. *Ann Thorac Surg* **73**: 892–899.
- Rodeck CH, Fisk NM, Fraser DI, Nicolini U. 1988. Long-term in utero drainage of fetal hydrothorax. *N Engl J Med* **319**: 1135–1138.
- Sade RM, Wiles HB. 1990. Pleuroperitoneal shunt for persistent pleural drainage after Fontane procedure. *J Thorac Cardiovasc Surg* **100**: 621–623.
- Sahn SA. 1990. The pathophysiology of pleural effusion. *Annu Rev Med* **41**: 7–13.
- Scott-Emuakpor AB, Warren ST, Kapur S, Quiachon EB, Higgins JV. 1981. Familial occurrence of congenital pulmonary lymphangectasias. Genetic implications. *Am J Dis Child* **135**: 532–534.
- Seeds JW, Bowes WA. 1986. Results of treatment of severe hydrothorax with bilateral pleuroamniotic catheters. *Obstet Gynecol* **68**: 577–580.
- Sepulveda W, Galindo A, Sosa A, Diaz L, Flores X, de la Fuente P. 2005. Intrathoracic dislodgment of pleuro-amniotic shunt. *Fetal Diagn Ther* **20**: 102–105.
- Skoll MA, Sharland GK, Allan LD. 1991. Is the ultrasound definition of fluid collection in nonimmune hydrops fetalis helpful in defining the underlying cause or predicting outcome? *Ultrasound Obstet Gynecol* **1**: 309–312.
- Smolencic J, James D. 1995. Predictive value of pleural effusions in fetal hydrops. *Fetal Diagn Ther* **10**: 95–100.
- Tanemura M, Nishikawa N, Kojima K, Suzuki Y, Suzumori K. 2001. A case of successful fetal therapy for congenital chylothorax by intrapleural injection of OK-432. *Ultrasound Obstet Gynecol* **18**: 371–375.
- Tarim E, Oguzkurt P, Kilicdag E, et al. 2004. Spontaneous regression and reaccumulation of pleural effusion in a fetus. *Fetal Diagn Ther* **19**: 410–412.
- Thompson PJ, Greenough A, Nicolaidis KH. 1993. Respiratory function in infancy following pleuro-amniotic shunting. *Fetal Diagn Ther* **8**: 79–83.
- Tsukihara A, Tanemura M, Suzuki Y, Sato T, Tanaka T, Suzumori K. 2004. Reduction of pleural effusion by OK-432 in a fetus complicated with congenital hydrothorax. *Fetal Diagn Ther* **19**: 327–331.
- Vaughan J, Fisk NM, Rodeck CH. 1995. Fetal pleural effusion. In *Invasive Fetal Testing and Treatment*, Harman CR (ed.). Blackwell Scientific Publications: Boston, MA; 219–239.
- Waller K, Chaithongwongwatthana S, Yamasmit W, Donnenfeld AE. 2005. Chromosomal abnormalities among 246 fetuses with pleural effusions detected on prenatal ultrasound examination : factors associated with an increased risk of aneuploidy. *Genet Med* **7**: 417–421.
- Webb RD, Walkinshaw SA, Shaw NJ. 2000. Cosmetic sequelae of thoraco-amniotic shunting. *Eur J Pediatr* **159**: 133–138.
- Weber AM, Philipson EH. 1992. Fetal pleural effusion: a review and meta-analysis for prognostic indicators. *Obstet Gynecol* **79**: 281–286.
- Wittman BK, Martin KA, Wilson RD, Peacock D. 1997. Complications of long-term drainage of fetal pleural effusion : case report and review of the literature. *Am J Perinatol* **14**: 443–447.